

Points

- Full-length radiographs can now be obtained using one single exposure
- These are extremely useful for assessing curvature abnormalities in the spine and lower limbs

Full-Length Radiographs

- Dr. G. R. Jankharia

Full-length radiographs particularly of the spine and lower extremity are very useful for scoliosis, kyphosis of the spine, limb-length discrepancy as well as alignment of the bones of the lower extremity, e.g. varus and valgus deformities.

For the spine, radiographs are taken in the standing position using a special cassette holder. After the exposure, the images are stitched on the computer and one entire image of the spine from C1 to the sacro-iliac joints is obtained. There is only one exposure.

Following points are noted:

1. Spine is straight or there is lateral curvature.
2. Scoliosis of less than 10° is considered insignificant.
3. Apex of the scoliotic curve is noted and the apical vertebra is analyzed for any wedging, fusion, rotation etc.
4. The angle of scoliosis is measured by Cobb's method and angle more than 20° is followed up.
5. Primary or secondary curve is judged by scannograms obtained in the AP standing position with right and left bending.
6. Scoliosis whether stable or unstable can be judged by drawing a straight line from the center of C7 to the center of the sacrum. If the line does not cut the center of the sacrum, it is unstable.

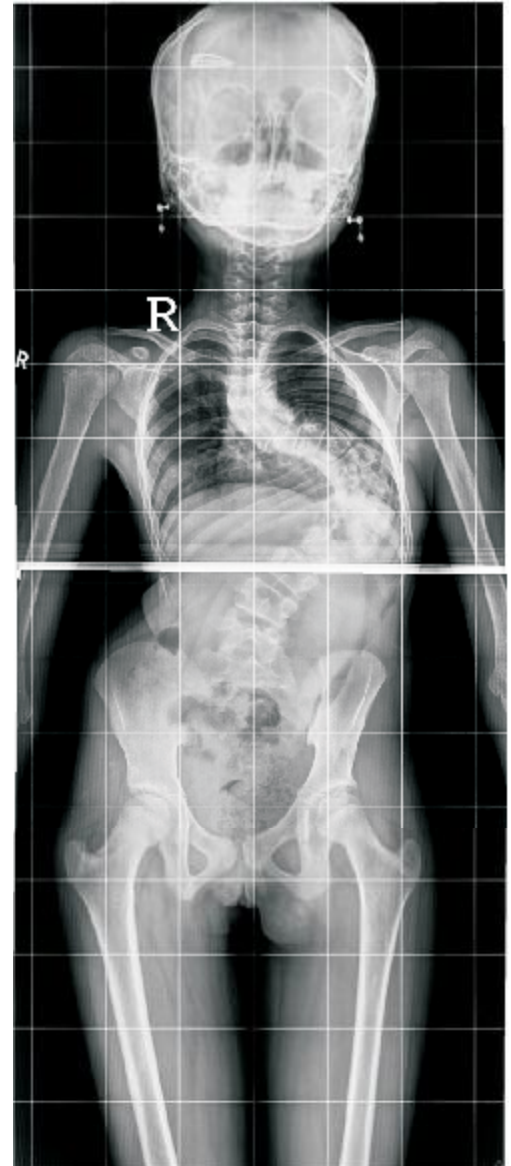


Fig. 1A

The online version is up at <http://www.piramaldiagnosics.com/radiology/spaces-newsletter/current-issue.aspx>

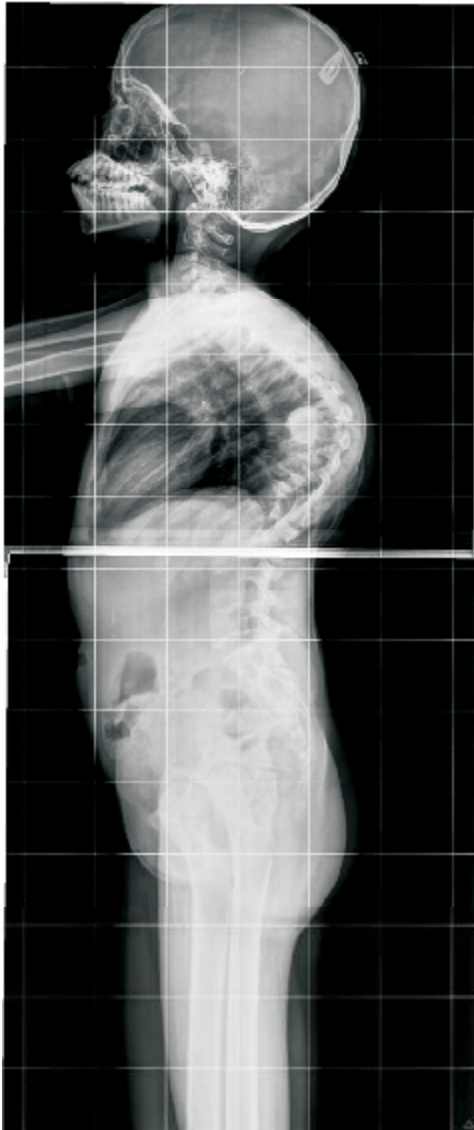

Fig. 1B

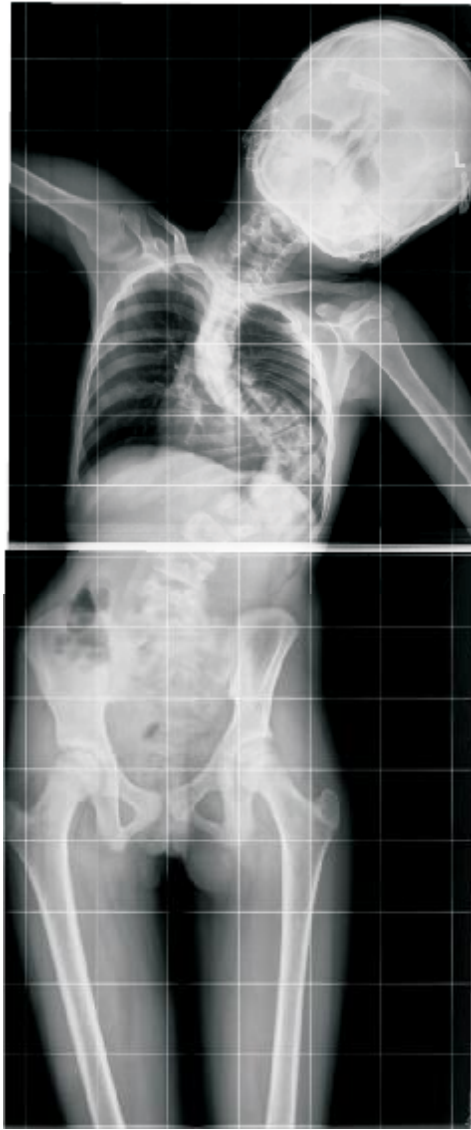

Fig. 1C

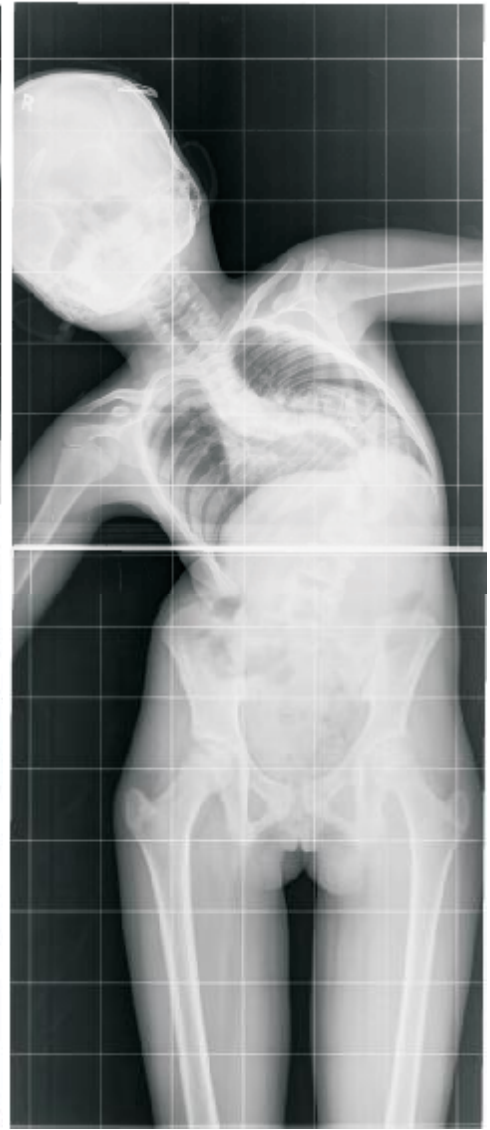


Fig. 1D

Figure 1 (A-D): Kypho-scoliosis. The AP radiograph (A) shows dorsal scoliosis with convexity to the left with a secondary curve in the lumbar spine along with gross dorsal kyphosis (B). Cobb's angle is minimally decreased with left lateral bending (C) and increased with right lateral bending (D).

Designed by



Main Clinic

Bhaveswar Vihar,
383, Sardar V. P. Road,
Mumbai-400004
Tel: 022-6617 3333.
Email: info@jankharia.com

Cardiac & Ultra fast CT scan

Nishat Business Center, Arya
Bhavan, 461, Sardar V. P. Road,
Mumbai-400004
Tel: 022-2389-3551
Fax: 022-2382-9595

PET/CT and 3T-fMRI

Piramal Tower Annexe.
Ground floor, Next to A to Z Ind.
Estate, G K Marg, Off Worli Naka,
Lower Parel, Mumbai - 400 013.
Tel: 6617 4444

Subscribe at

info@jankharia.com

Owner, Printer & Publisher: Dr. Bhavin Jankharia, Published at: Dr. Jankharia's Imaging Center, Bhaveswar Vihar, 383, S.V.P.Road, Prarthana Samaj, Mumbai 400 004.
Printed at: India Printing House, First Floor, 42, G D Ambekar Marg, Opp. Wadala Post Office, Wadala, Mumbai 400 031.