



USG Guided Supraclavicular Node Biopsy

- Dr. Saba Shaikh

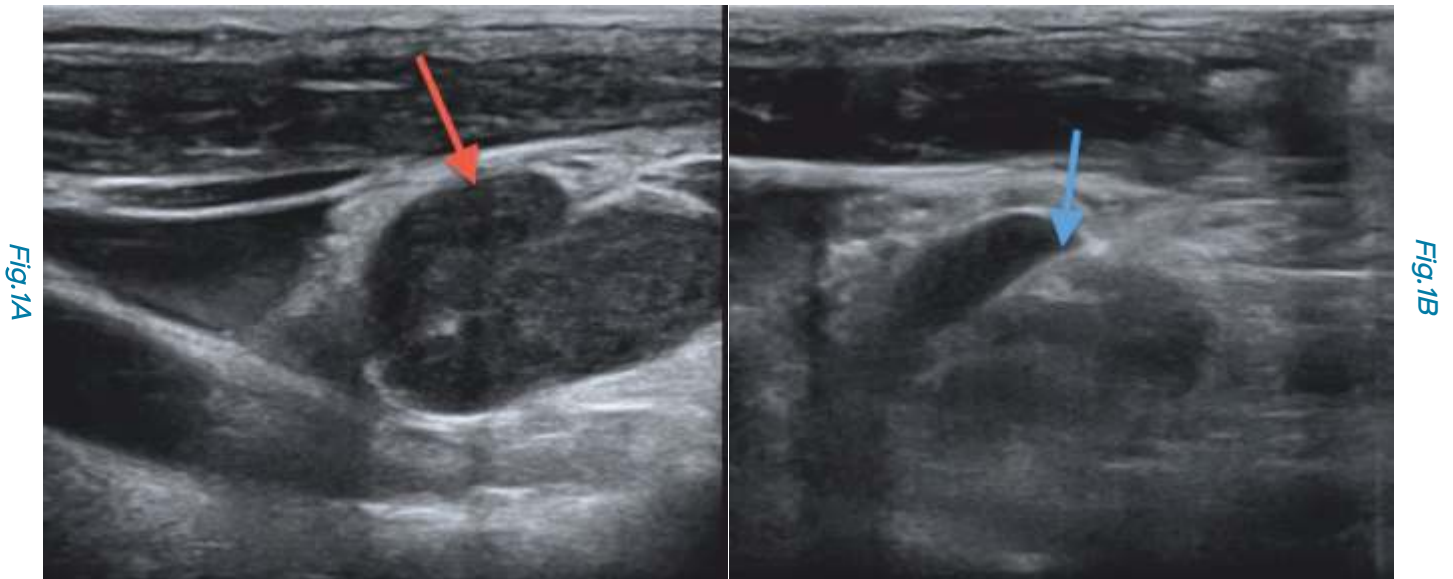


Figure 1 (A,B): Tuberculosis. This 24-years old girl has necrotic mediastinal and right supraclavicular lymphadenopathy. USG (A) shows the necrotic node (red arrow). Under USG guidance a biopsy (blue arrow) of the node was obtained and confirmed necrotizing granulomatous disease on histopathology with acid-fast bacilli seen on smear.

In many patients with pyrexia of unknown origin (PUO) or lymphadenopathy of unknown etiology (LUE), an enlarged supraclavicular node is often the only lymph node that is easily accessible for histopathology and microbiology.

Traditionally, surgical excision biopsy of supraclavicular nodes has been the standard of care for obtaining histopathologic and microbiologic diagnoses.

However, USG guided supraclavicular node biopsy in expert hands can be equally diagnostic and can save the trauma of surgery.

USG provides a better window of approach, especially for small nodes that are close to neck vessels, because it is real-time and the operator can moderate the entire procedure taking care to see that there is no damage to the adjacent structures, especially the neurovascular bundles. Also, it is important to biopsy along the long axis of the node, which can be done easily under USG guidance.



At a glance

- Enlarged supraclavicular nodes are often the only accessible nodes in patients with PUO or extensive lymphadenopathy
- USG in expert hands can easily guide core biopsies of these node
- Under USG guidance, the vessels and nerves can be avoided and biopsies can be obtained through the longitudinal axis of the nodes

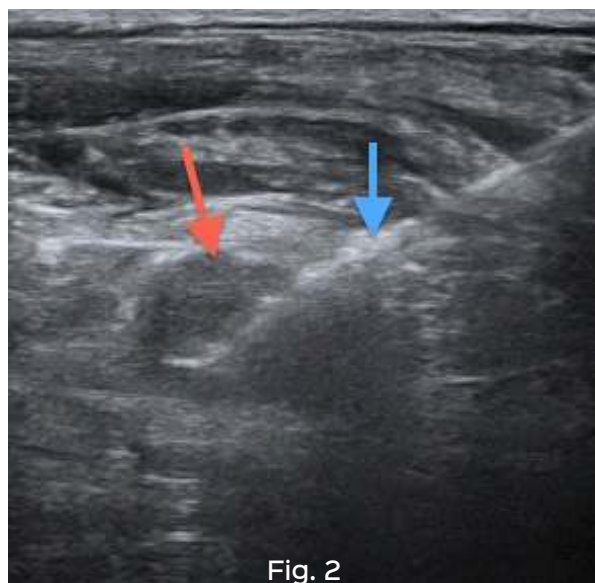


Fig. 2

Figure 2: Metastatic adenocarcinoma from thyroid. This 48-years old man had generalized adenopathy, osseous lesions and a tiny thyroid lesion, which was of questionable significance. Under USG guidance, the left supraclavicular lymph node (red arrow) was biopsied (blue arrow) and showed metastasis from thyroid carcinoma.

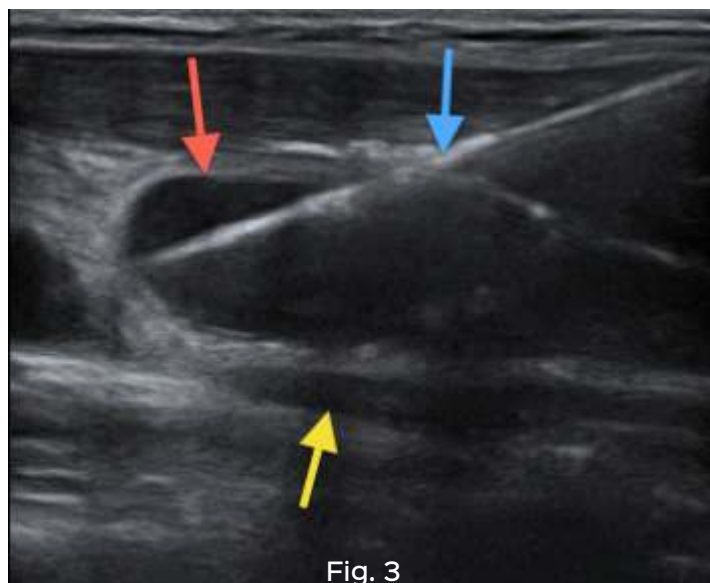


Fig. 3

Figure 3. Tuberculosis. This 22-years old girl had necrotic right supraclavicular adenopathy (red arrow), close to the major vessels (yellow arrow). USG allowed the core biopsy gun (blue arrow) to be deployed easily without any risk of damage to the vessels.

These procedures are always performed using a coaxial technique, with multiple cores obtained for histopathology, microbiology and these days, GeneXpert.

Subscribe to INNER SPACES : info@jankharia.com

Online version : <http://picture-this.in/index.php/inner-spaces/>

Main Clinic

383 | Bhaveshwar Vihar | Sardar V. P. Road | Prarthana Samaj | Charni Road | Mumbai 400 004 | T: 022 66173333 | F: 022 2382 9595

Cardiac, Chest & Interventional CT

461 | Nishat Business Centre | Arya Bhavan | Sardar V. P. Road | Mumbai 400 004 | T: 022 2380 2172 | 022 2389 3551 / 2

PET / CT, Organ Optimized 3T MRI

Gr. Floor | Piramal Tower Annexe | G. K. Marg | Lower Parel | Mumbai 400 013 | T: 022 6617 4444

Owner, Printer & Publisher: Dr. Bhavin Jankharia

Published at: Dr. Jankharia's Imaging Centre

Bhaveshwar Vihar, 383, S.V.P. Road, Prarthana Samaj, Charni Road, Mumbai 400 004.