



Cryoablation

There are many tumor ablation techniques. Radiofrequency ablation (RFA) has been around for the last 16 years and we have used it for bone tumors such as osteoid osteoma, osteoblastoma and chondroblastoma and liver, and lung malignancies, with good success. However, RFA uses thermal energy and the exact diameter of ablation always remains a guesstimate.

Cryoablation is a new technique where freezing temperatures are used to kill tumor cells by creating ice-balls within the tumors. Liquid nitrogen or argon is used depending on the system. With liquid nitrogen, the temperature at

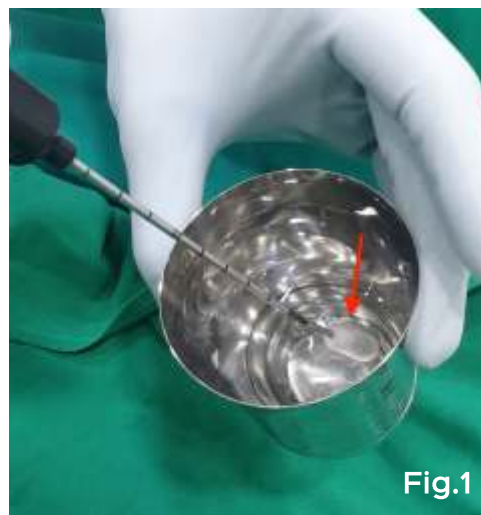


Fig. 1: Ice-ball (red arrow) at the tip of the cryoprobe, during pre-procedure testing.

Fig.1

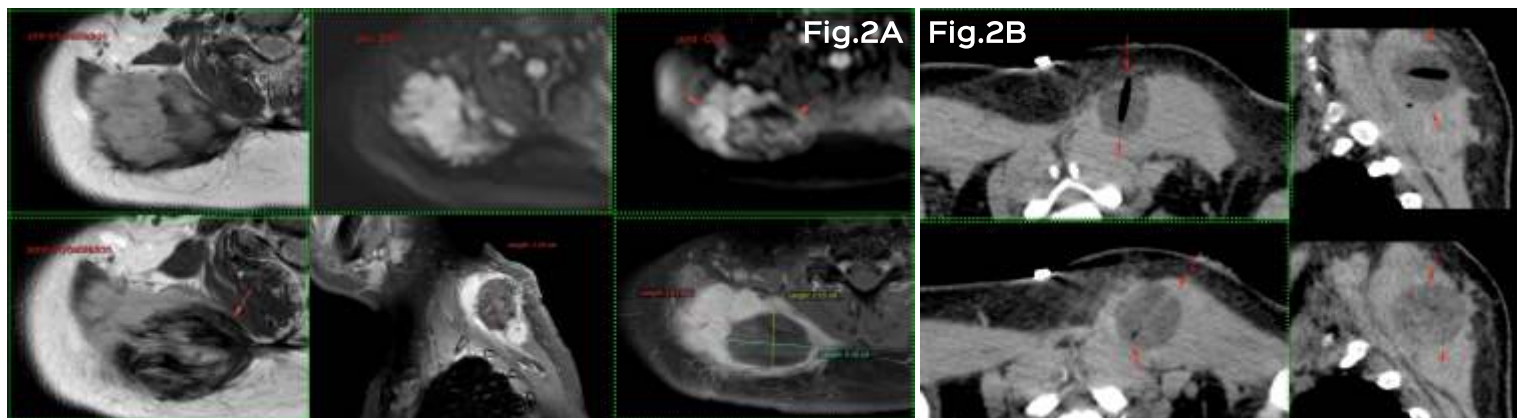


Fig.2A

Fig.2B

Fig. 2 (A,B): 47-years old lady with right upper thoracic wall fibromatosis. Two ablations were done under intravenous sedation, with a freeze-thaw-freeze time of 15-15-15 minutes (A). Both ice-balls are seen well (A). A repeat MRI one week later shows 70% necrosis (B).

the centre of the ice-ball can reach up to minus 196 degrees Celsius with lethal temperatures of minus 20 to minus 40 degrees in the rest of the ice-ball (Fig. 1). More importantly, the ice-ball can be visualized on USG, CT or MRI as the case may be, allowing accurate monitoring of the ablation area (Figs. 2, 3).

The machine is compact and sits in the CT scan room (Fig. 4). The procedure is easily done on an out-patient basis in day-care, mostly under local anesthesia (Fig. 3), some patients needing intravenous sedation if the tumors are inherently painful (Fig. 2).

Indications

1. Bone tumors including osteoid osteoma, osteoblastoma for cure and metastases, for palliation



At a glance:

- ◆ Cryoablation is a new ablation technique that uses ice-balls to freeze and kill tumor cells
- ◆ It is now available in India
- ◆ Virtually all indications for RFA are indications for cryoablation, with the advantage of being able to visualize the ablation zone much more accurately.

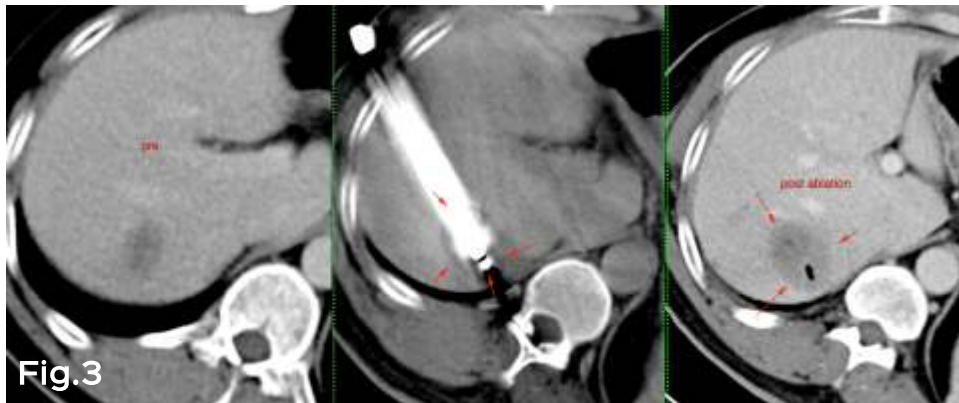


Fig. 3: 52-years old man with liver metastasis from abdominal leiomyosarcoma seen in the first panel, ablated under local anesthesia. The ice-ball (arrows) is well seen in the middle panel with the ablation zone incorporating a margin of 5 mm beyond the tumor. A single ablation was done with a freeze-thaw-freeze time of 15-15-15 minutes. The right panel shows the ablated size and the necrosis (arrows).

2. Soft tissue tumors like fibromatosis (Fig. 2) for cure and palliation
3. Lung tumors – primary and metastases
Liver tumors – primary and metastases (Fig. 3)
4. Renal tumors
5. Breast fibroadenomas
6. Cryo-immunotherapy – where cryoablation also incites a generalized anti-tumor response.

Contraindications

1. Large tumor size (typically > 5 cm)
2. Abnormal coagulation profile

Videos of both cases are available at

www.ctbiopsy.com/cryo01 and www.ctbiopsy.com/cryo02

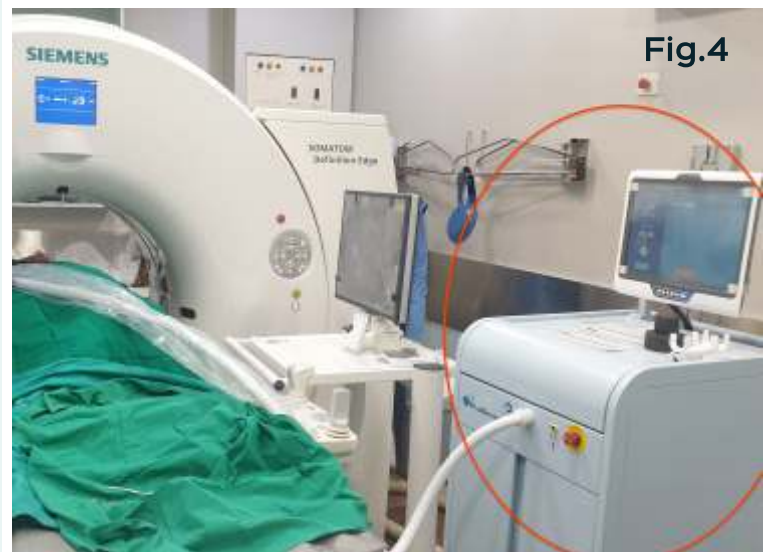

Fig. 4: The compact (red circle) cryoablation machine (IceCure, Israel) in the CT scan room at the time cryoablation.

Subscribe to INNER SPACES : info@jankharia.com

Online version : <http://picture-this.in/index.php/inner-spaces/>

Main Clinic

383 | Bhaveshwar Vihar | Sardar V. P. Road | Prarthana Samaj | Charni Road | Mumbai 400 004 | T: 022 66173333

Cardiac, Chest & Interventional Twin Beam CT

Nishat Business Centre | Arya Bhavan | 461 | Sardar V. P. Rd | Next to Marwari Vidyalaya | Mumbai 400 004 | T: 022 6848 6666

PET / CT, Organ Optimized 3T MRI

Gr. Floor | Piramal Tower Annexe | G. K. Marg | Lower Parel | Mumbai 400 013 | T: 022 6617 4444

Owner, Printer & Publisher: Dr. Bhavin Jankharia

Published at: Dr. Jankharia's Imaging Centre

Bhaveshwar Vihar, 383, S.V.P. Road, Prarthana Samaj, Charni Road, Mumbai 400 004.